

Testimonial

Catherine, veterinarian, Stavropol Region/Moscow, October 2010



We bought battery-operated RIKTA-MV with two emitters in 2007 and used it according to the protocols recommended in the Operation Manual.

The first positive result: some Akhal-Teke* horses were delivered from Stavropol (South Russia) to the Moscow region in the very chilly fall of 2007: rains with cold winds. The horses started coughing, sneezing, snotty – we considered it as a very bad acclimatization.

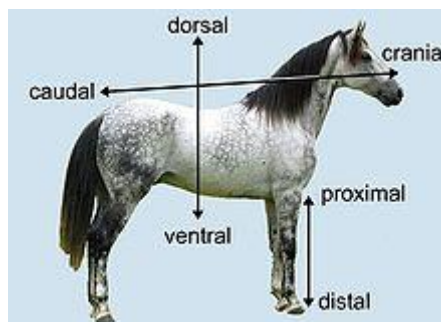
** Akhal-Teke is a horse breed from Turkmenistan, where it is a national emblem. These horses are famous for their speed and for endurance on long marches. These "golden-horses" are thought to be one of the oldest surviving horse breeds. There are currently about 3,500 Akhal-Tekes in the world).*



Only 3-4 days of treatment according to the protocols on rhinitis & laryngitis and suddenly and very deliberately all the symptoms had gone! We expected improvement, but not such a fast and clear evidence!

Besides problems of adaptation, one horse suffered from obstruction and very strong cough. In addition to conventional treatment, we used the protocol for emphysema - after one course of treatment the horse was quite recovered and we forgot about it.

...I like especially the acupuncture point on the tip of the tail called "Caudal spine".



If a horse is indisposed, par example, after it has been frozen, I used to make preventive stimulation of this point. No respiratory diseases at all!

Before a horse mating we stimulated all the mares with RIKTA-MV laser device (as recommended - superficially, in the lumbar/loin region).

All mares became pregnant, including the mare sold from a stud farm because they failed to cover it. All gave birth successfully, foals were strong and healthy. The mares keep reproductive system in a good state.

One day, in the 4th month of the gestation, the mares struggled for leadership inside the paddock, because they could not decide which one of them was "the best". That happens among thoroughbred horses full of vigor.

As a result of this skirmish:



1. The leading mare had enormous synovial swelling, size of 25-liter bucket on the frontal part of the right groin, a little stretched in length. Difficult to imagine this injury and now I regret that I didn't make pictures. Really, I had no time to do that when all this happened.
2. The other mare had a badly injured vulva, soft tissues crushed, superficial bleeding etc.



I thought miscarriage was inevitable for all of them. We treated them according to the protocols on bruises and swelling with help of antioedematic fluids.

No one has miscarried, nothing bad has happened...

3. If we have minor bruises, injuries, we use the RIKTA device and everything is OK without any bad consequences.

4. It is a very interesting suggestion to irradiate blood on the jugular vein before heavy physical activity - indeed, the horse becomes restless and recovers quickly.

Sincerely, Catherine