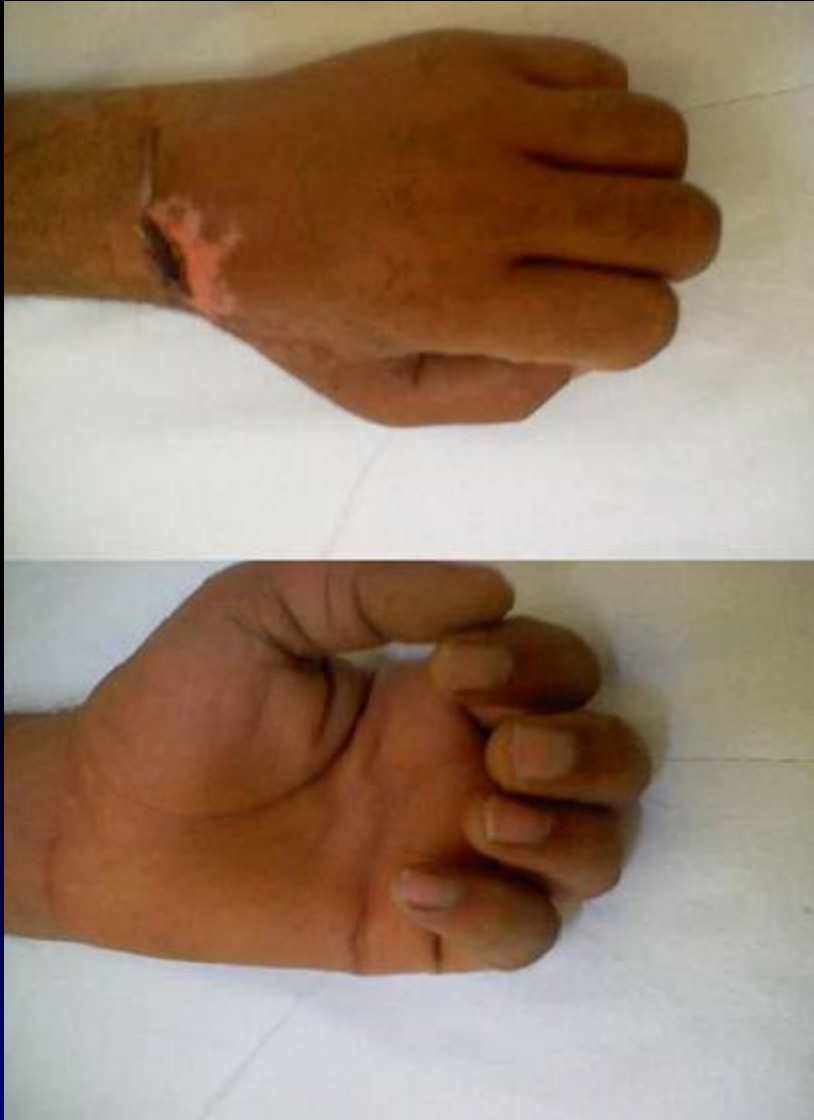

MEDICAL CASES OF DR.HUSSEIN, LEBANON

TheraNat SA Contact : courrier@theranat.com Tel 0041219223518 www.theranat.com

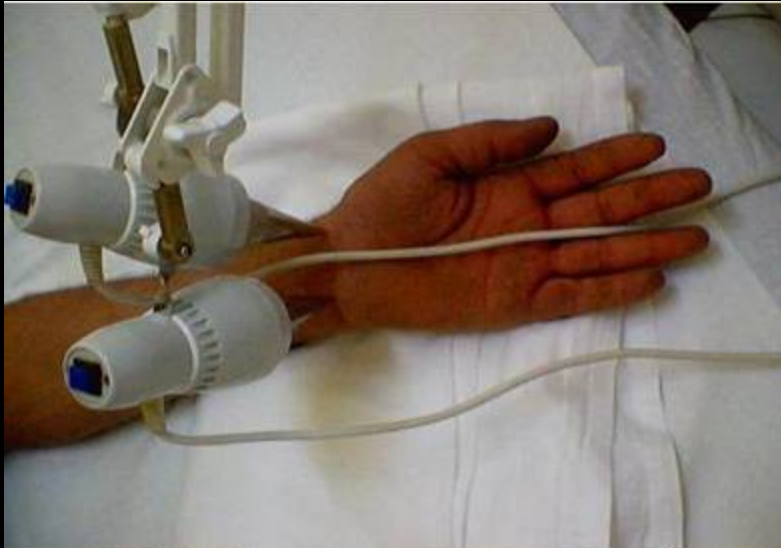COPYRIGHT TheraNat SA

1. Case from Dr.S.Hussein

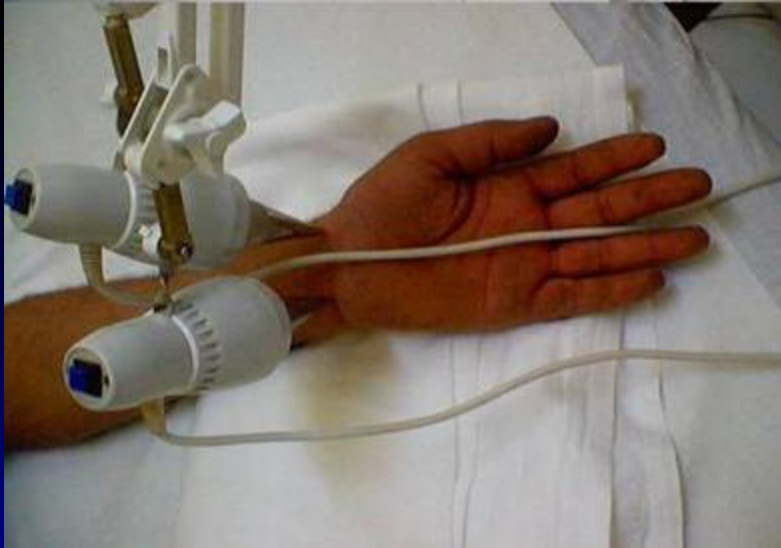

- 41 years old patient
- Work injury with cut of extensor tendons of left hand
- Patient wasn't able to close his fist

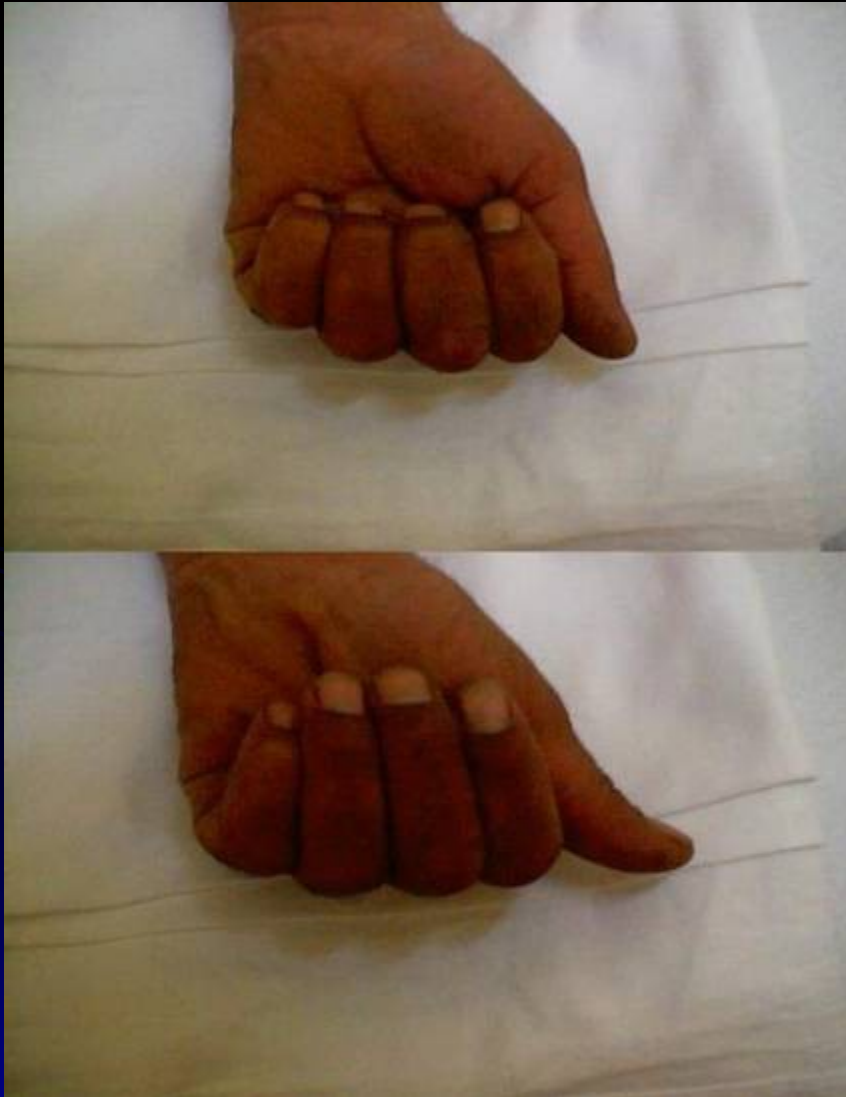
Case from Dr.S.Hussein



- MIL therapy was applied locally on the wound and on the anterior surface of wrist joint

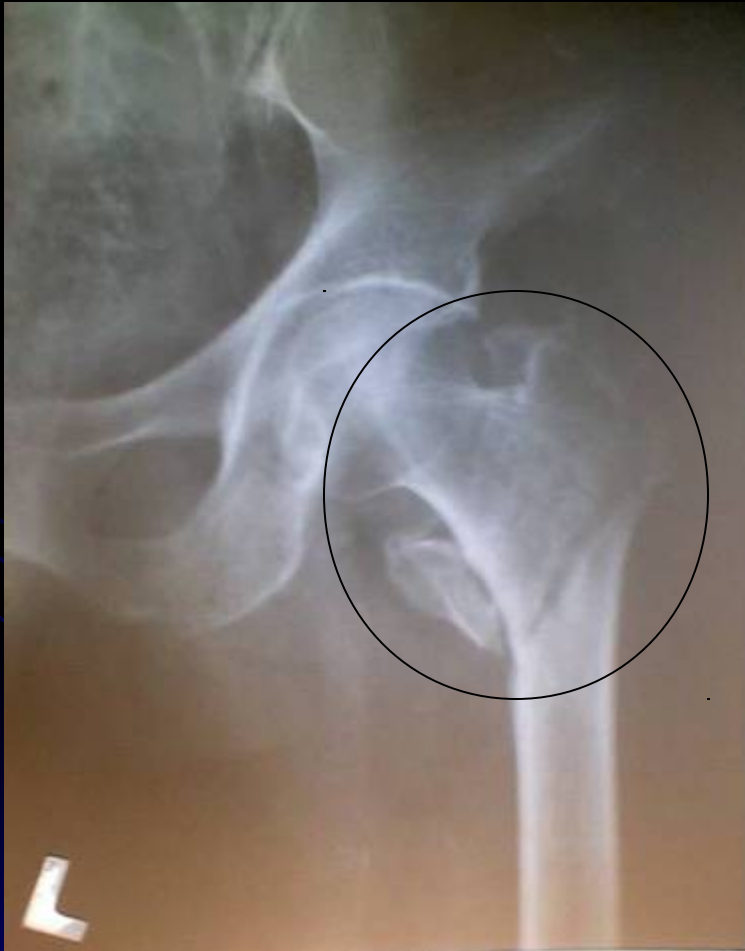

Case from Dr.S.Hussein



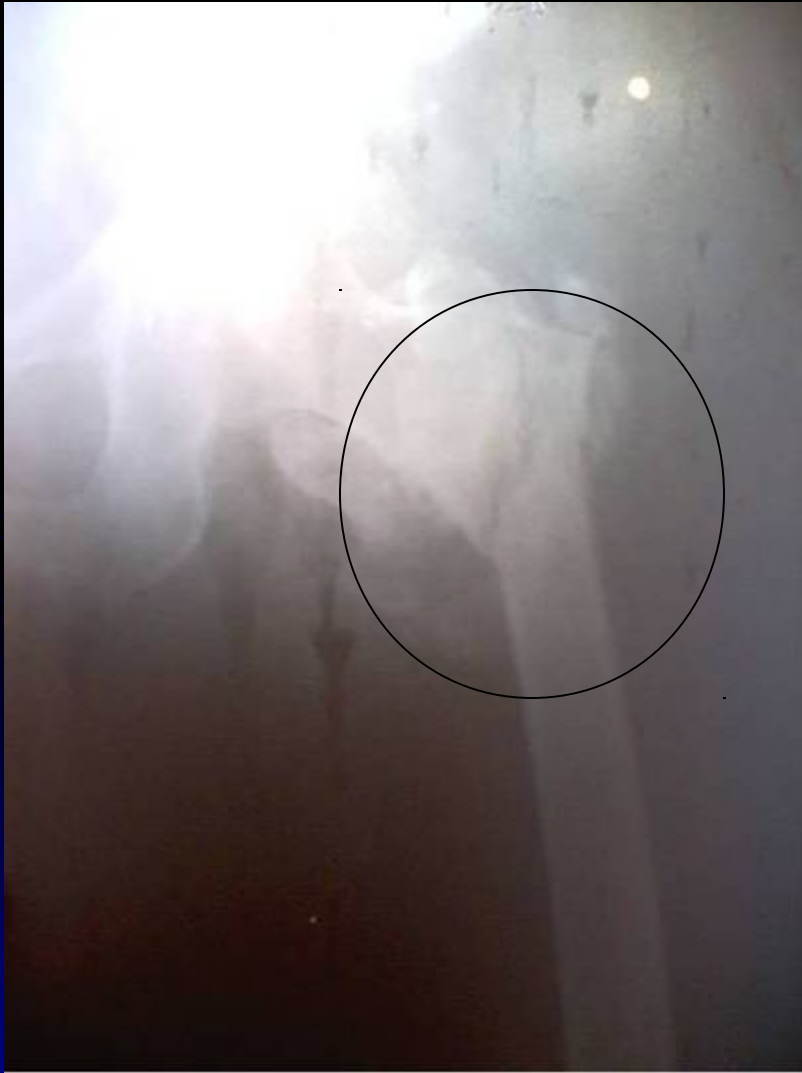- After 15 sessions of MIL therapy the hand regained its normal functions
- The patient was able to close his fist completely

2. Case from Dr.S.Hussein



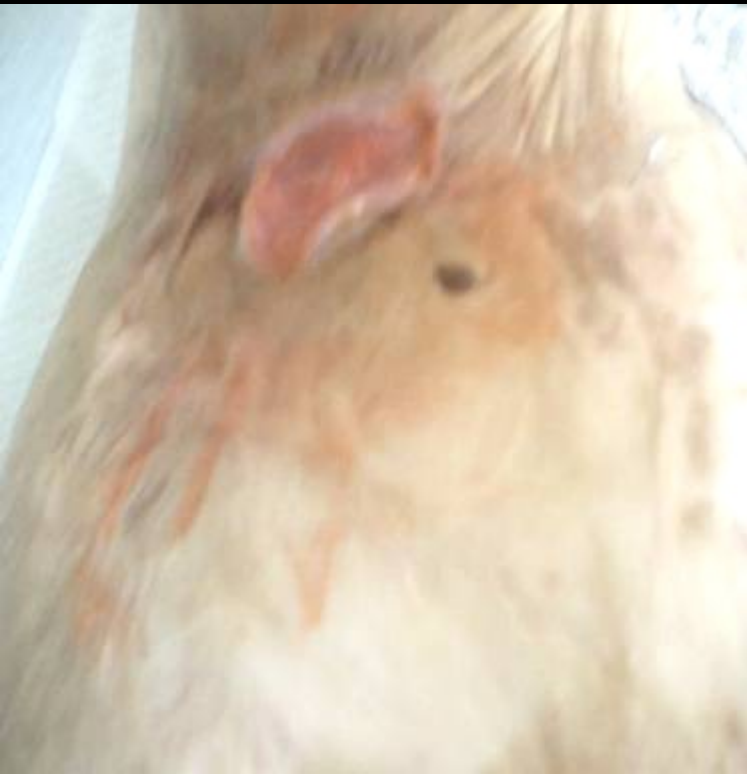- 94 years old woman diabetic, with petrochanteric fracture
- The X-ray shows the line of fracture

Case from Dr.S.Hussein

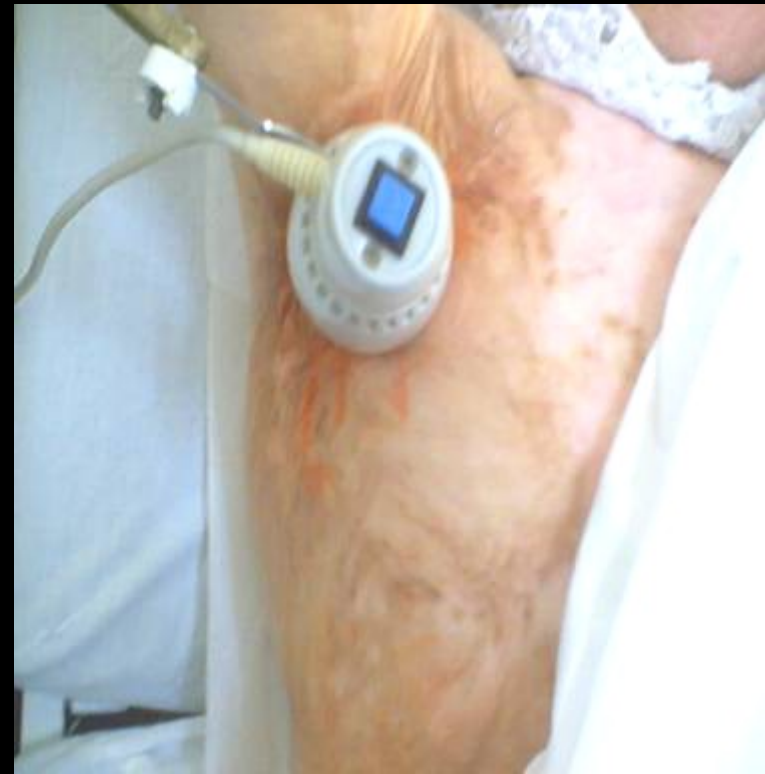

- After 15 sessions of MIL therapy calcification started to appear around the fracture

3. Case from Dr.S.Hussein

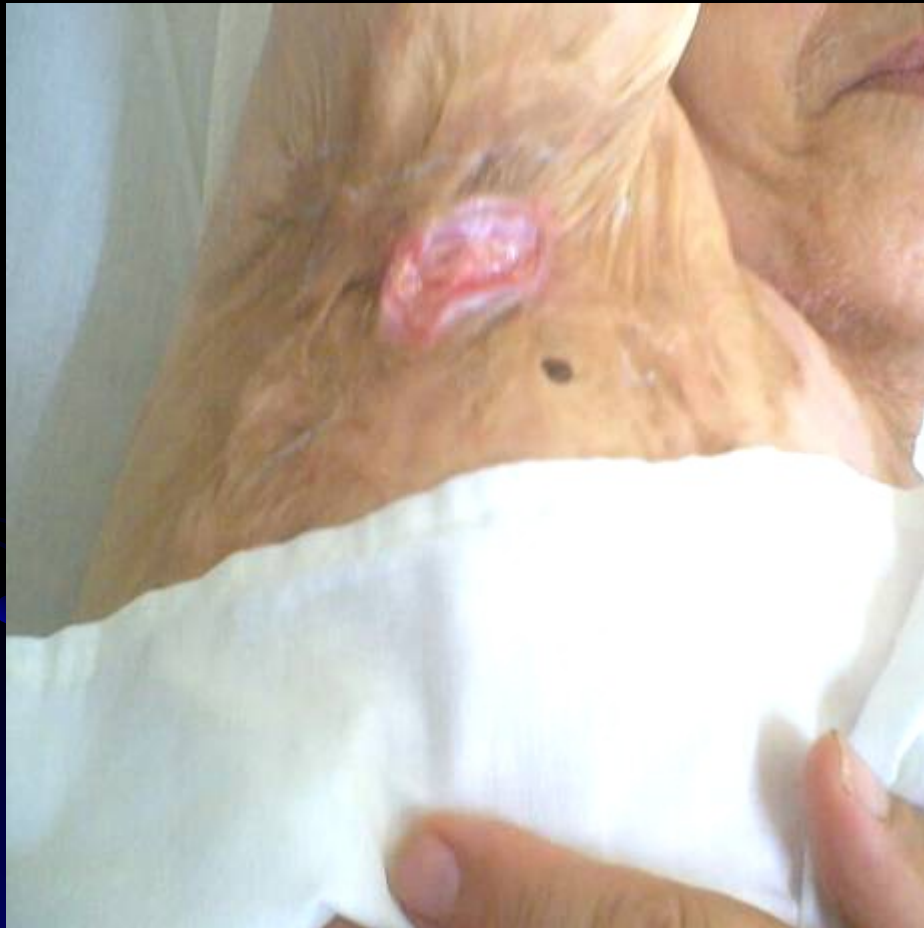

29-7-2003



- 64 years old woman
- Diabetic
- Old burn

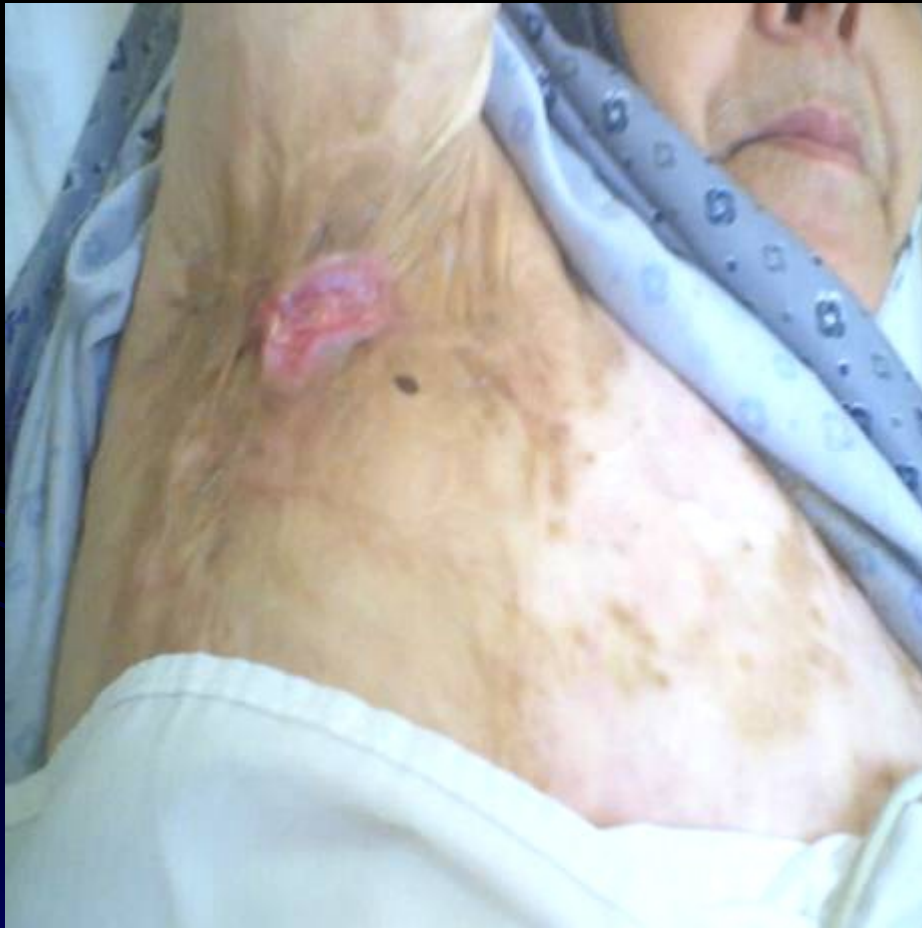Case from Dr.S.Hussein



After 6 days

4-8-2003

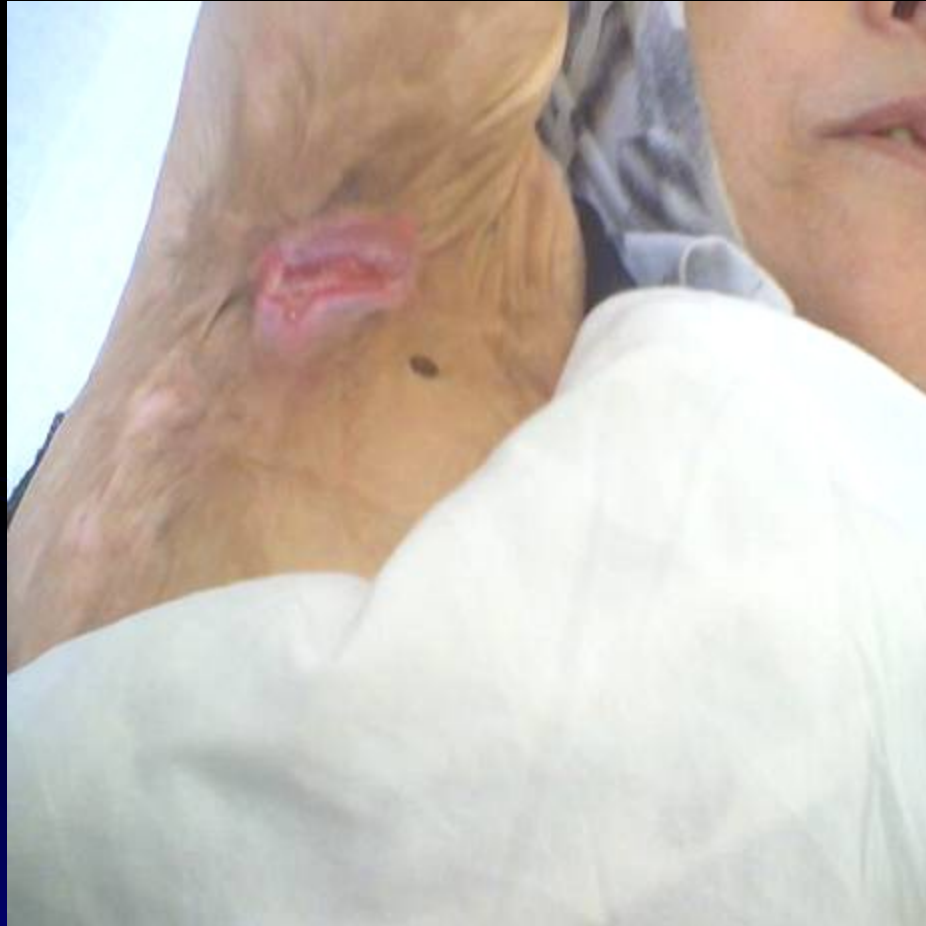Case from Dr.S.Hussein



After 9 days

7-8-2003

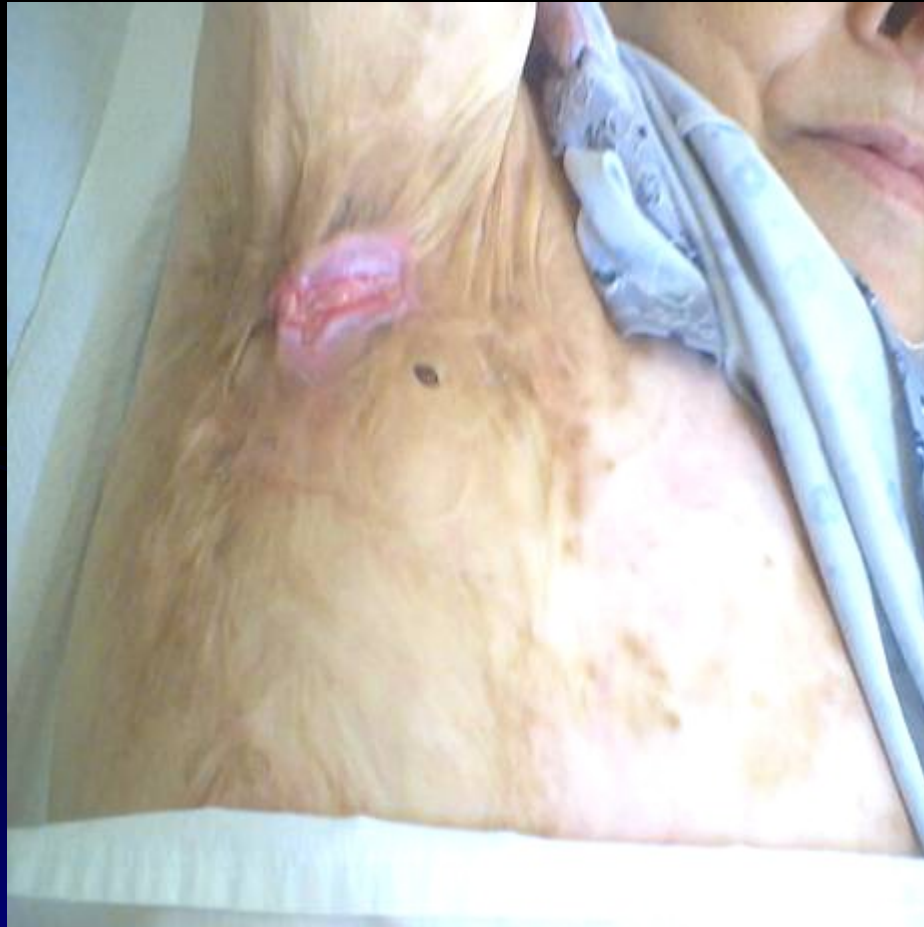Case from Dr.S.Hussein



After 9 days

12-8-2003

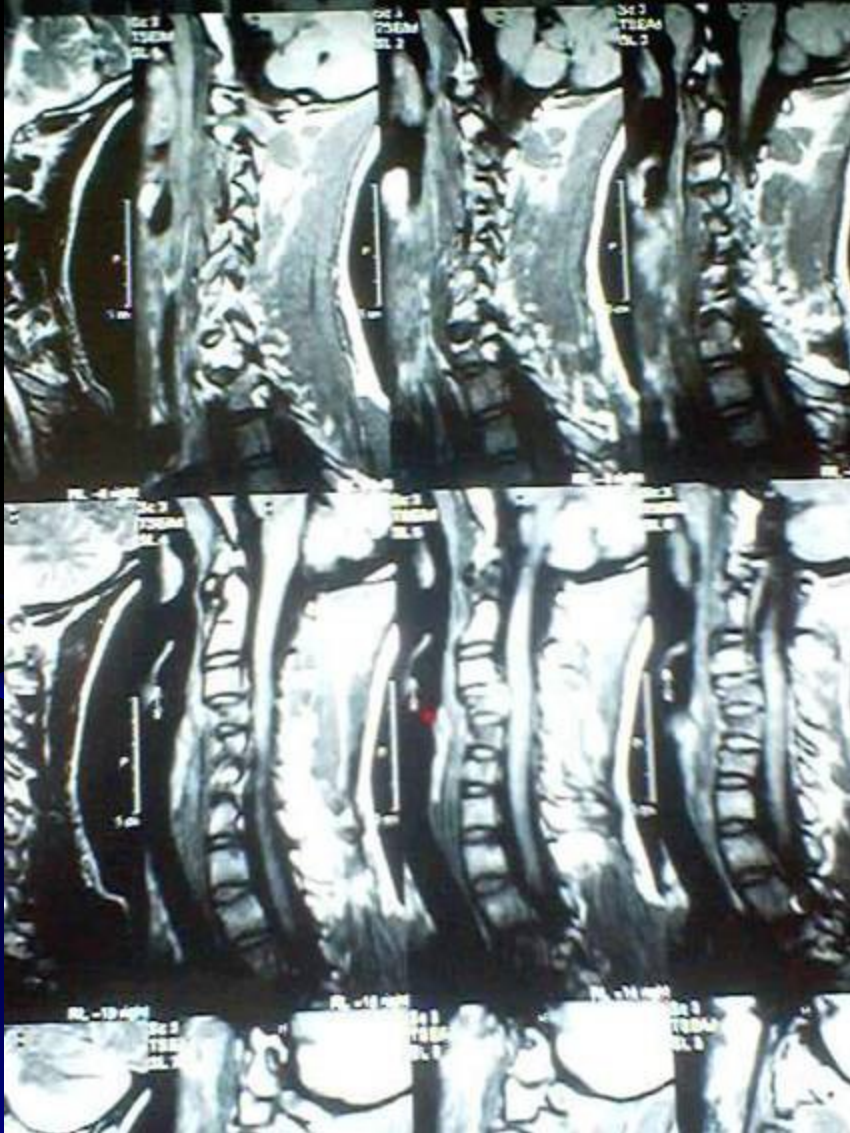
Case from Dr.S.Hussein



After 12 days

15-8-2003

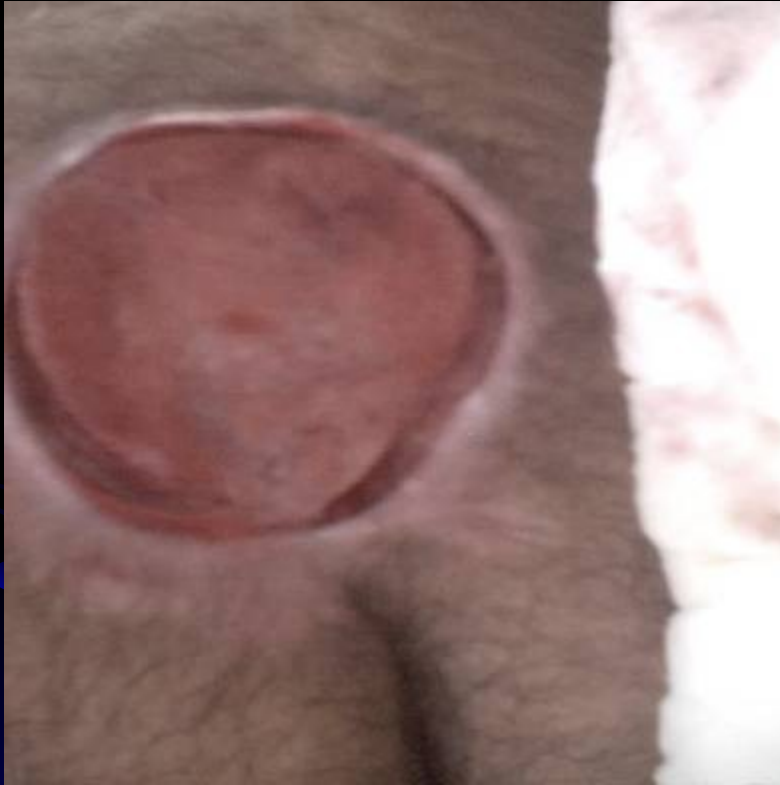4. Case from Dr.S.Hussein



- 17 years old patient
- Tetra-pelagic caused by car accident

5. Case from Dr.S.Hussein

Bed Sour of the tetra-pelagic patient

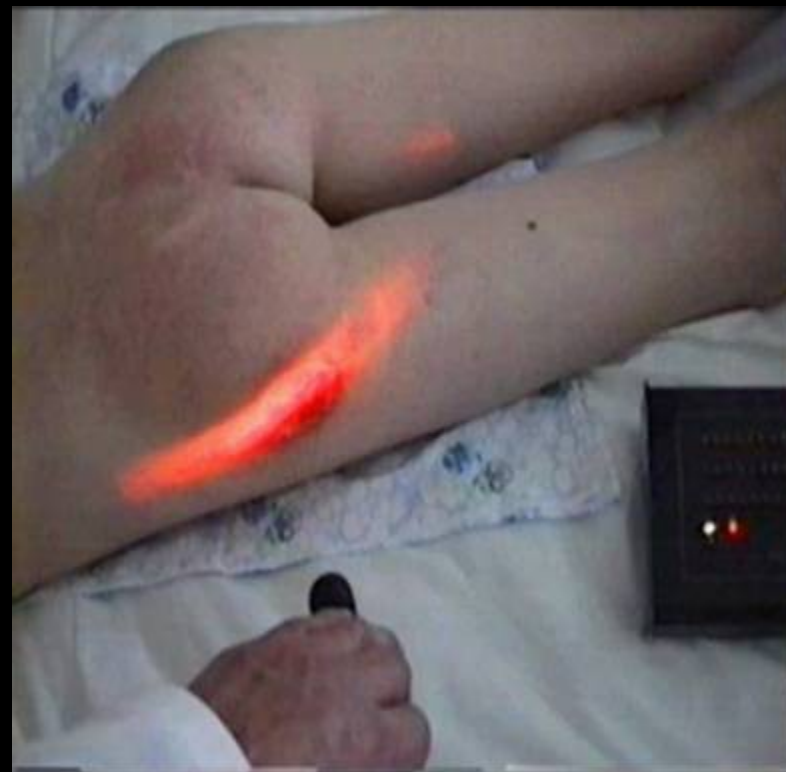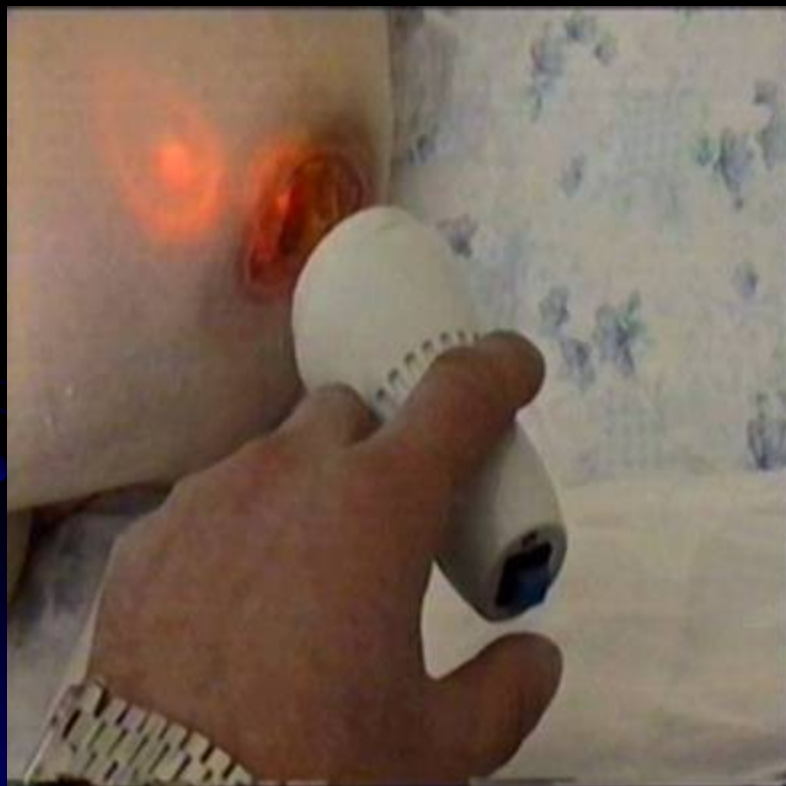


Before treatment



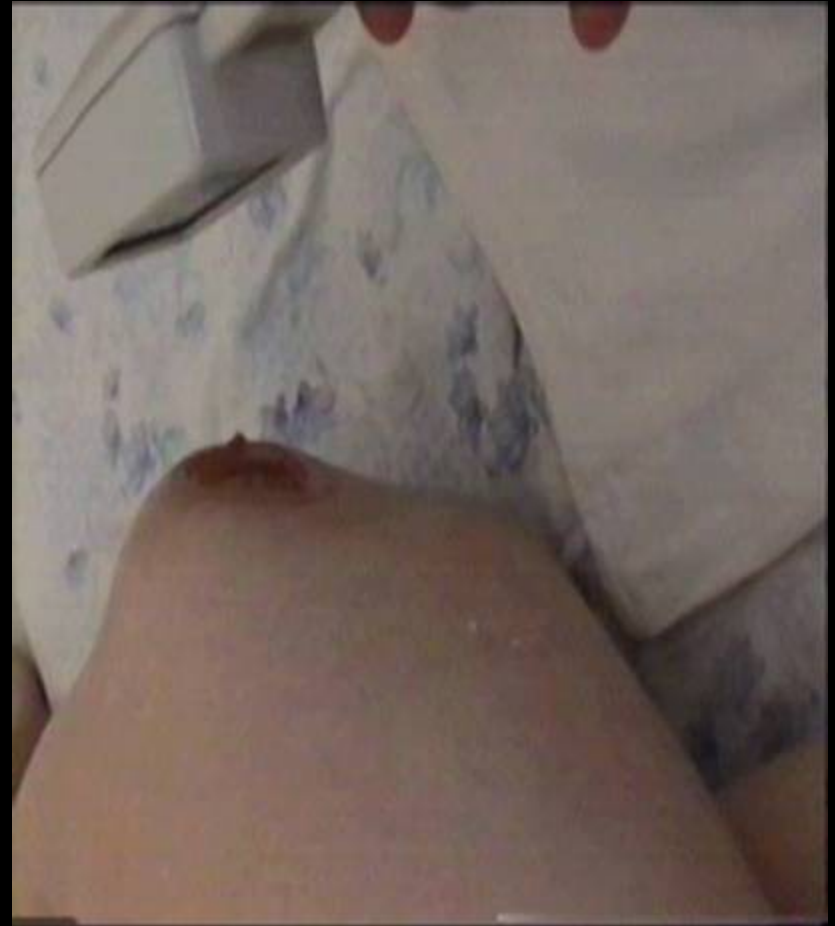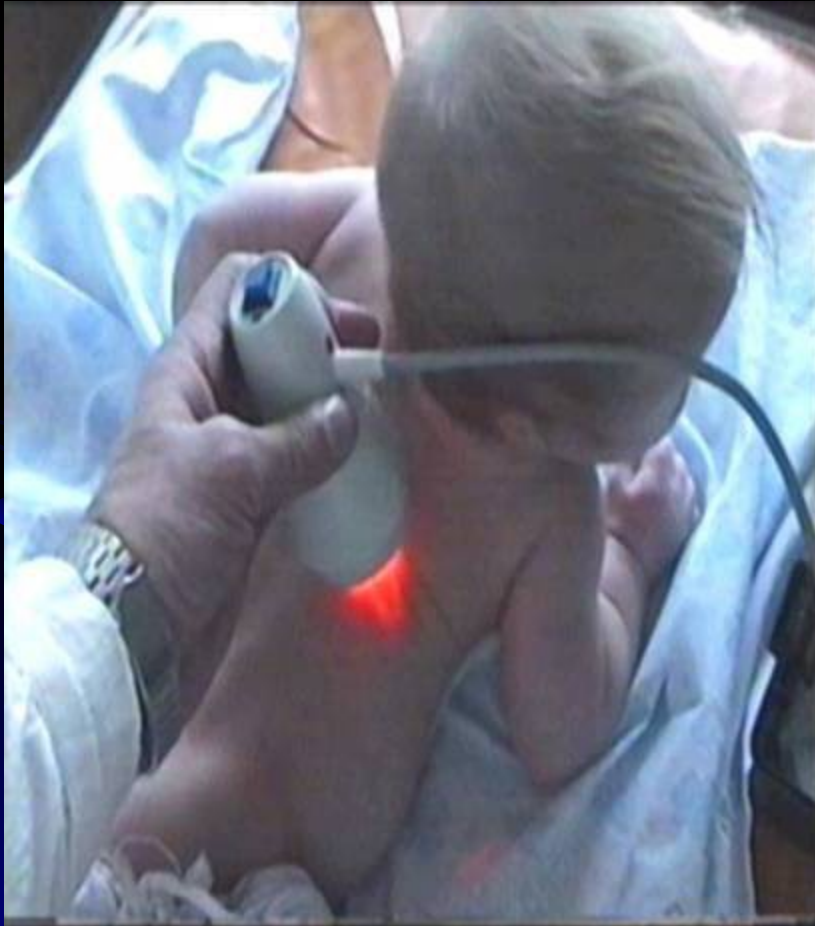After treatment

MIL therapy acting on a bed soure

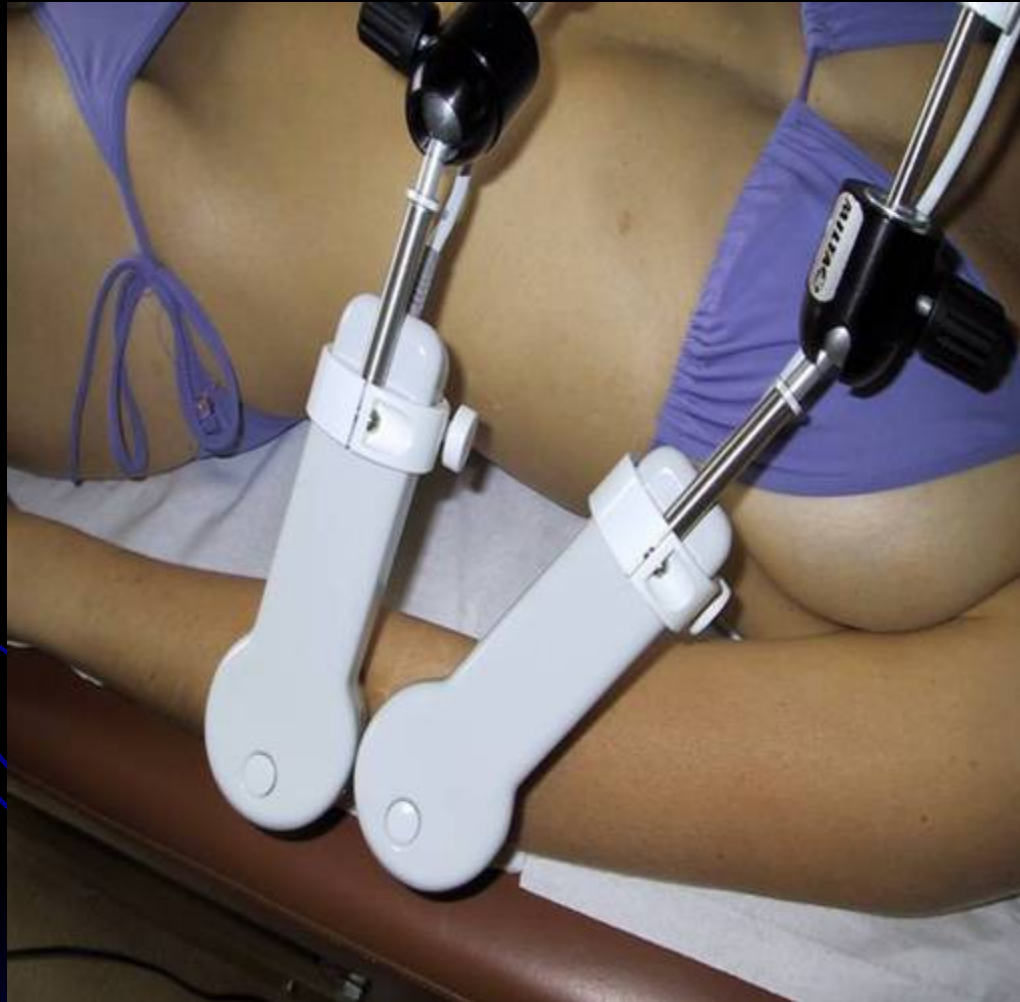

MIL THERAPY IN...

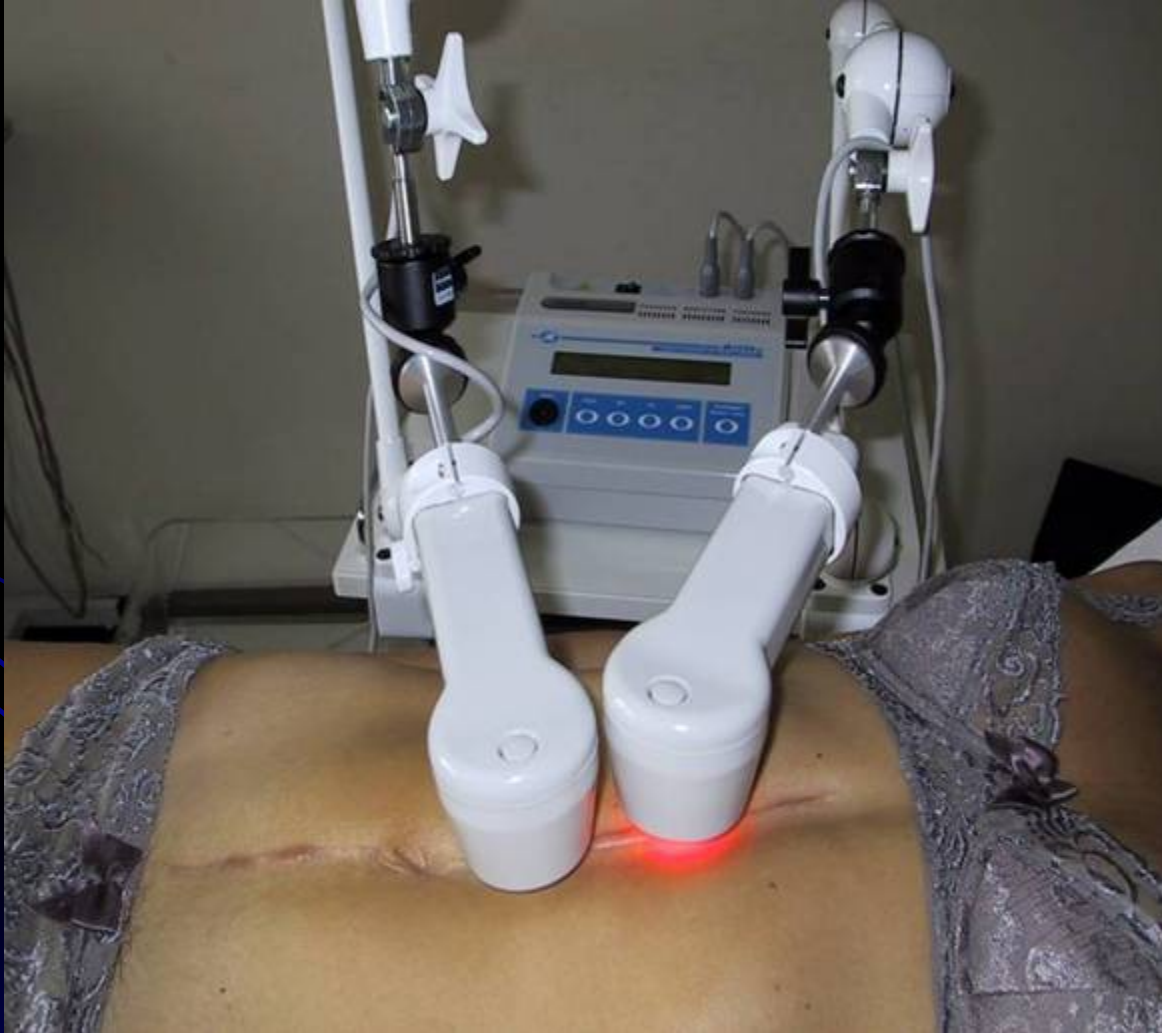MIL therapy in pediatrics



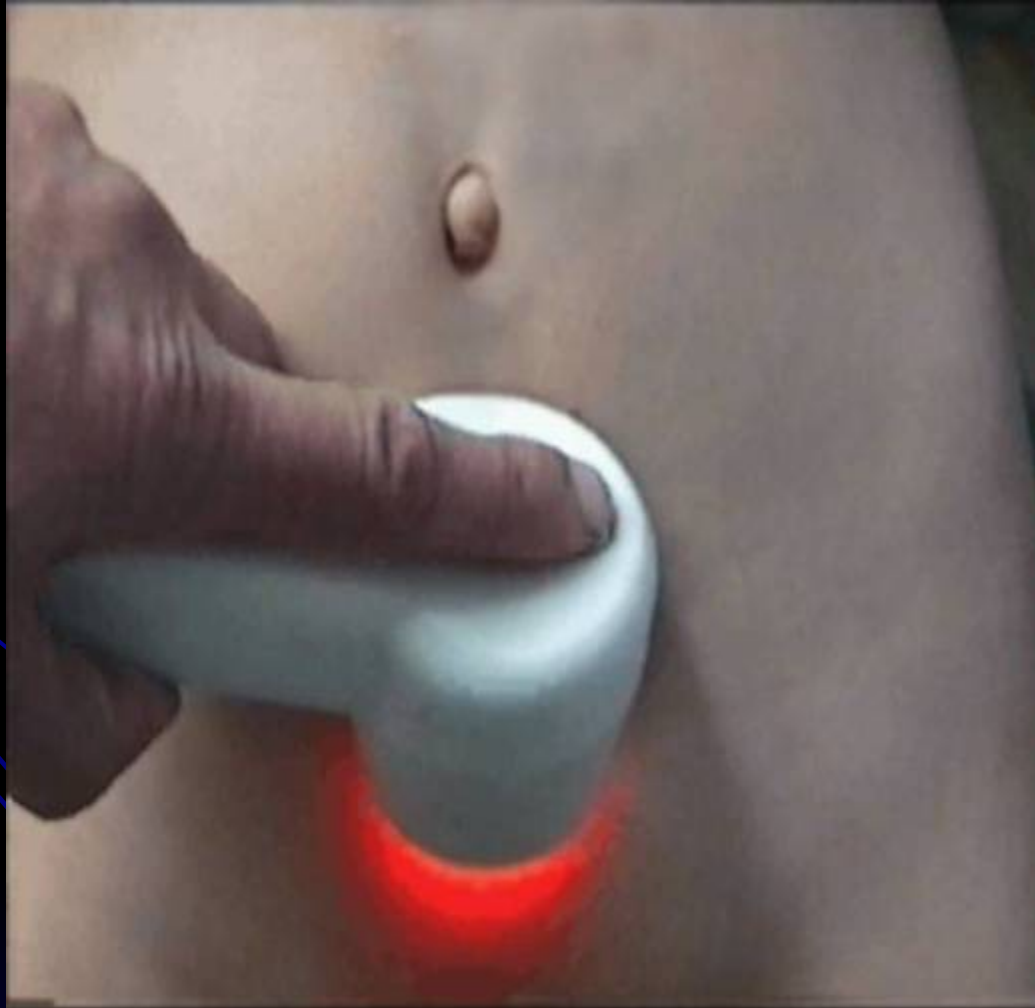
MIL Therapy in Treating Tennis Elbow



MIL in Post-Surgery Treatment



MILT in Treating Urology Complications

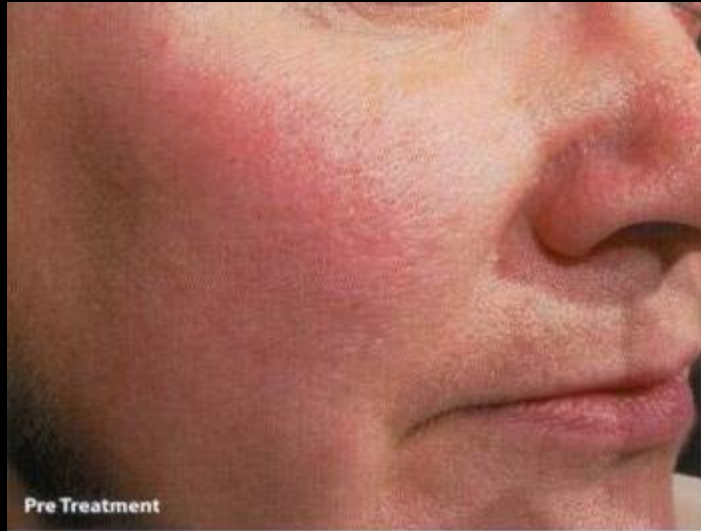

MIL Therapy in Dermatology

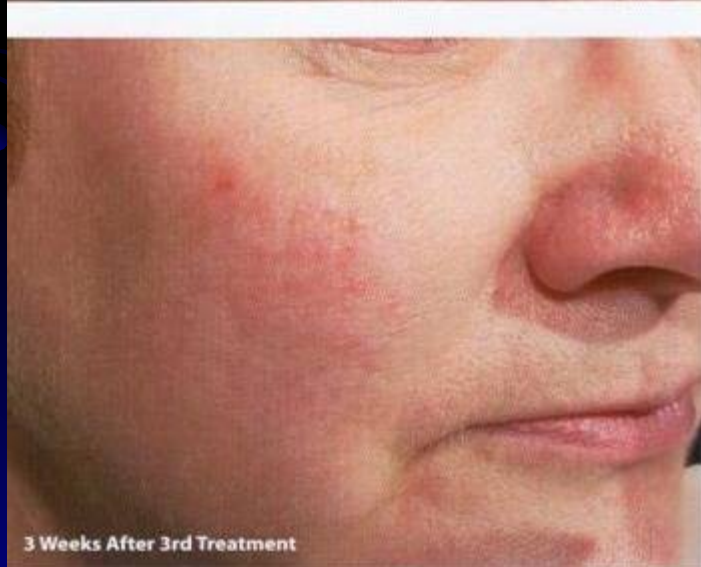TheraNat SA Contact : courrier@theranat.com Tel 0041219223518 www.theranat.com

COPYRIGHT TheraNat SA

Female Cheek Diffuse Redness



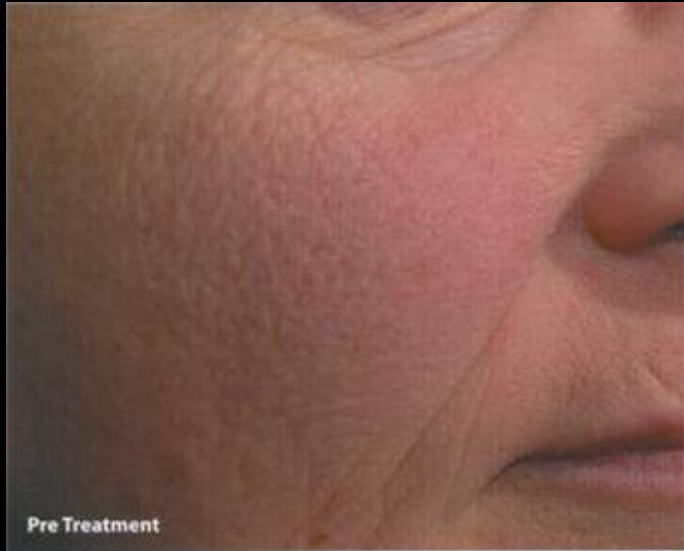Pre Treatment



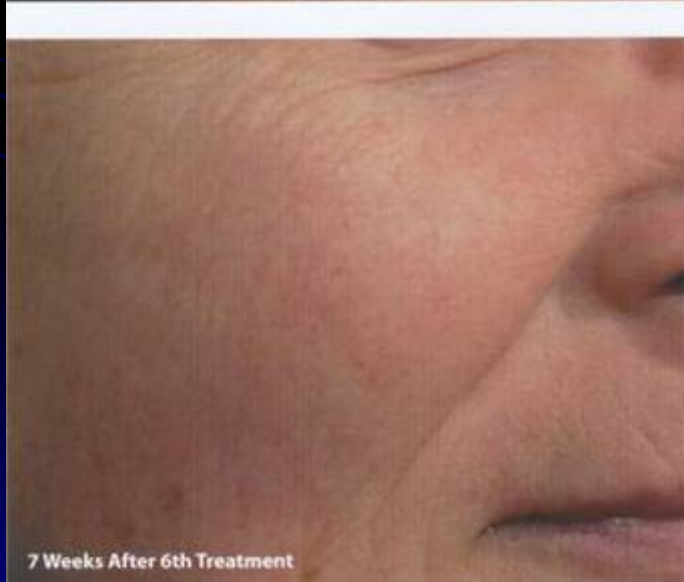Number of treatments: 3
3 weeks apart

After Treatment

Female Cheek Diffuse Redness



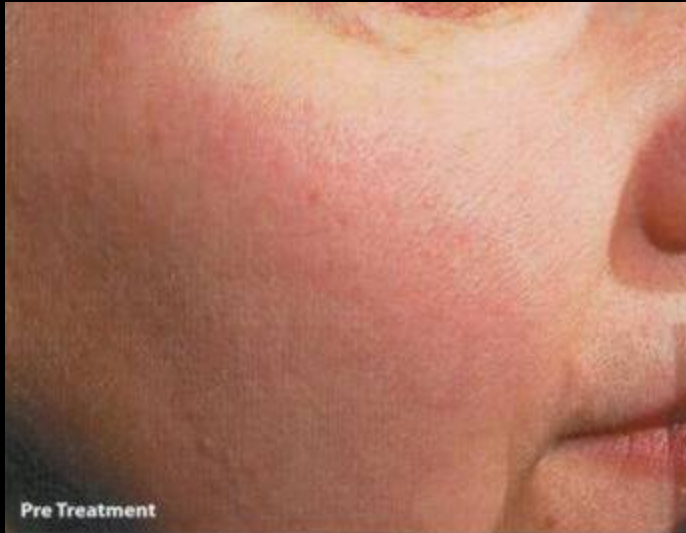Pre Treatment



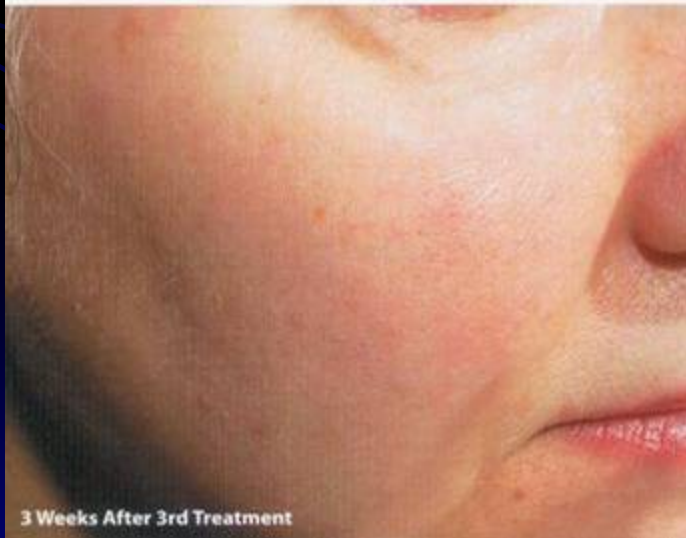Number of treatments: 6
2 weeks apart

After Treatment

Female Cheek Facial Telangiectasia



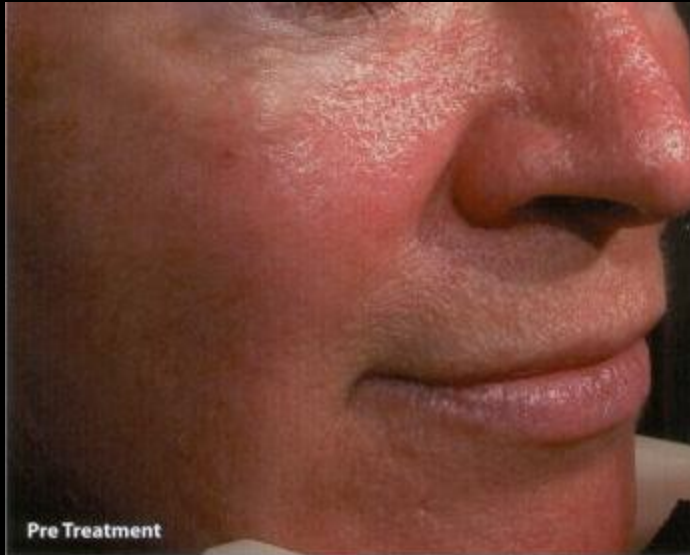Pre Treatment



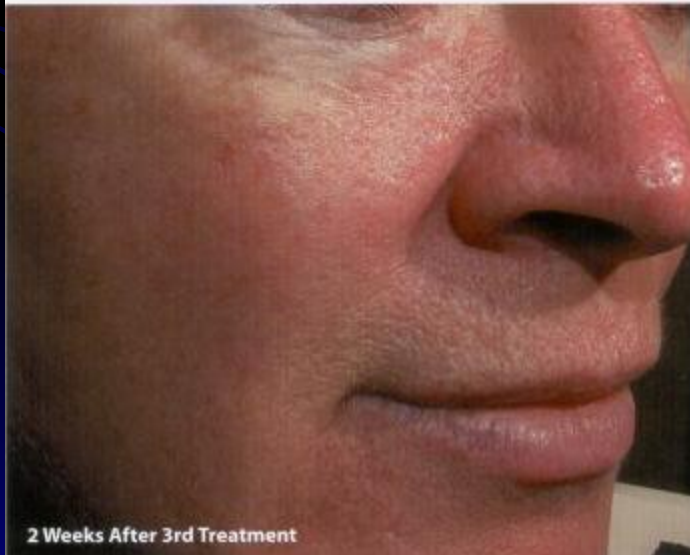After Treatment

Number of treatments: 3
3 weeks apart

Female Cheek facial Telangiectasia



Pre Treatment



After Treatment

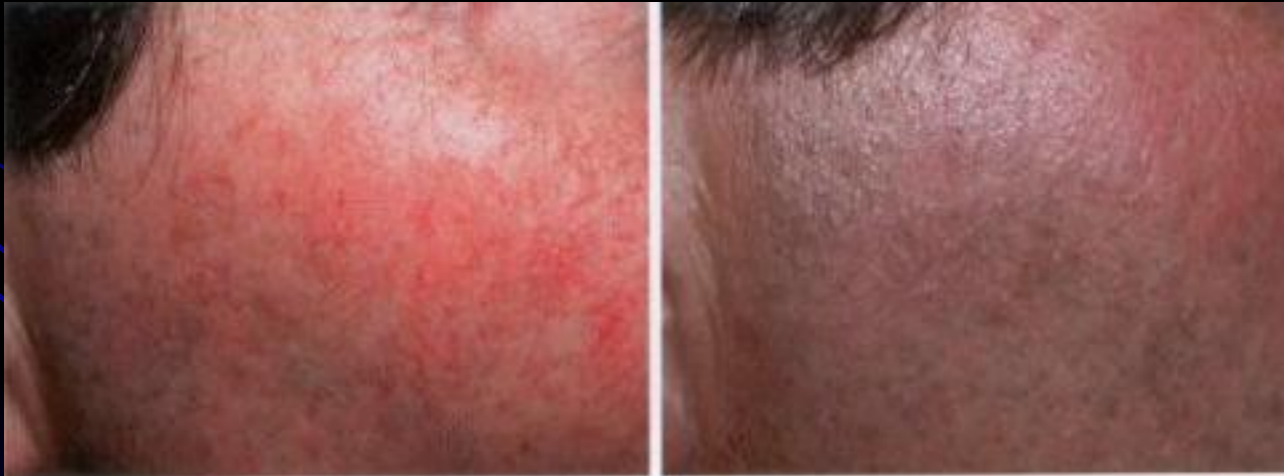Number of treatments: 3
2 weeks apart

Male Cheek facial Telangiectasia

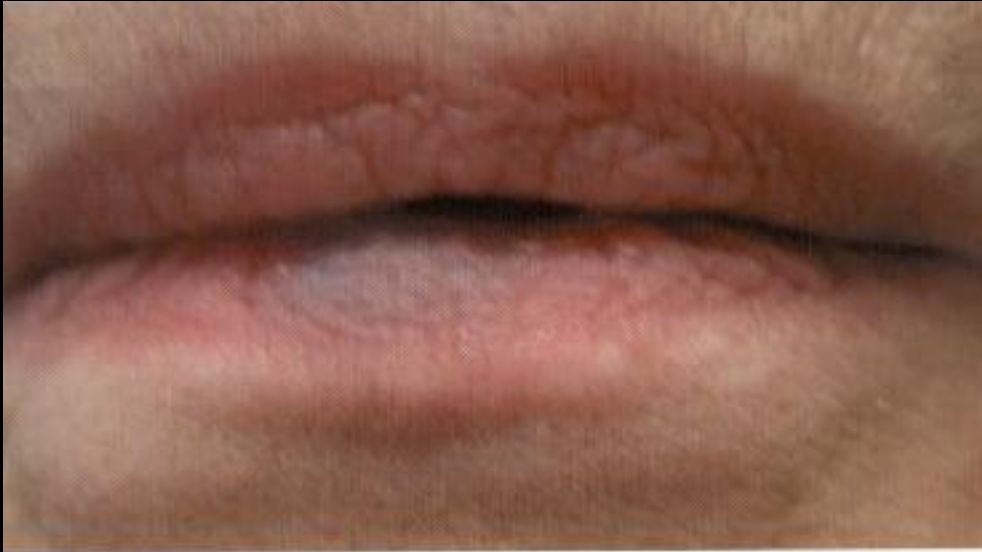Pre Treatment

Number of treatments: 1

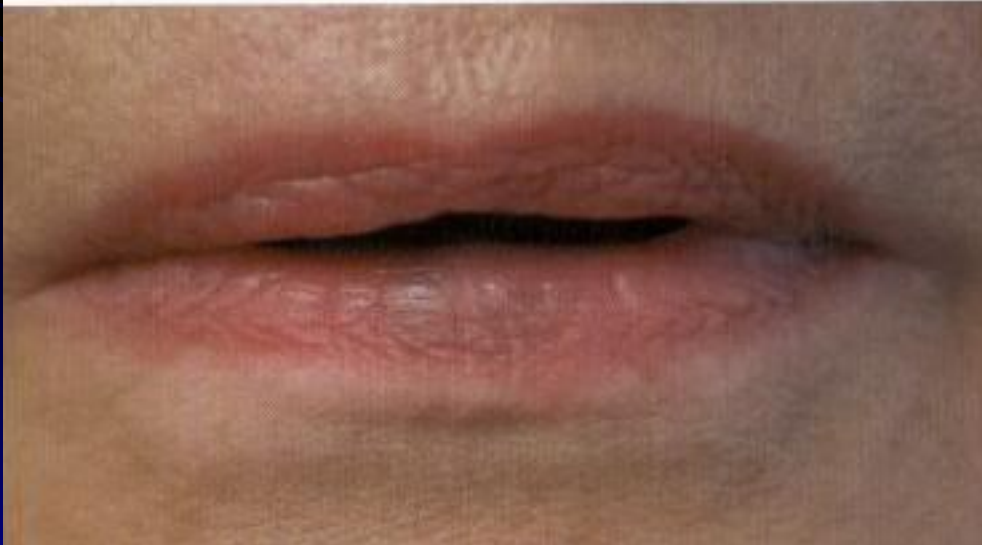After Treatment



Female Lip Venous Lake



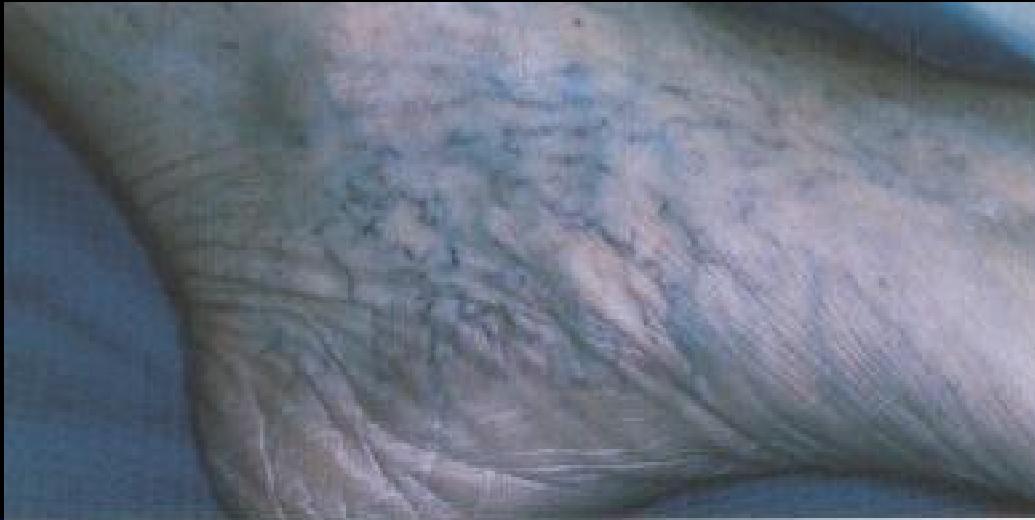Pre Treatment



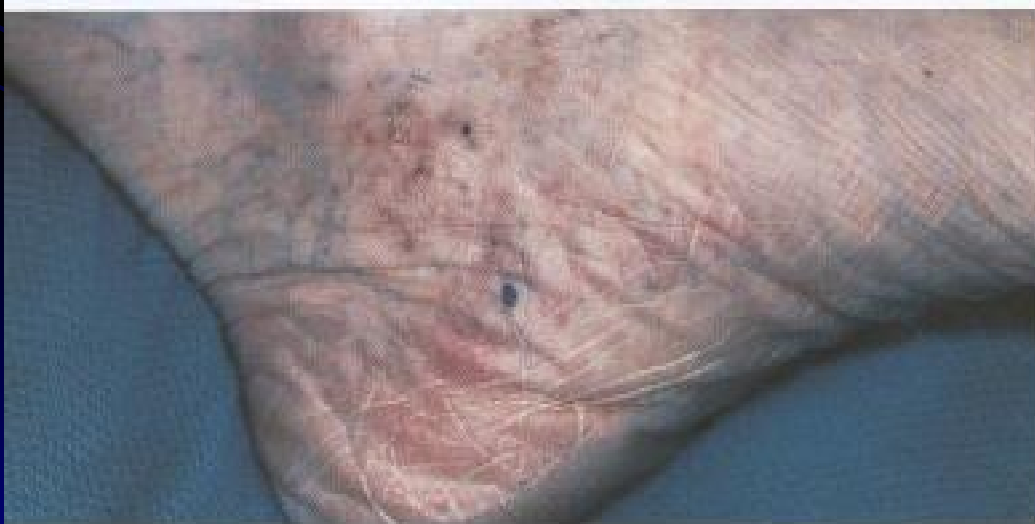Number of treatments: 1
1 month after treatment

After Treatment

Female Left Media Ankle telangiectasia



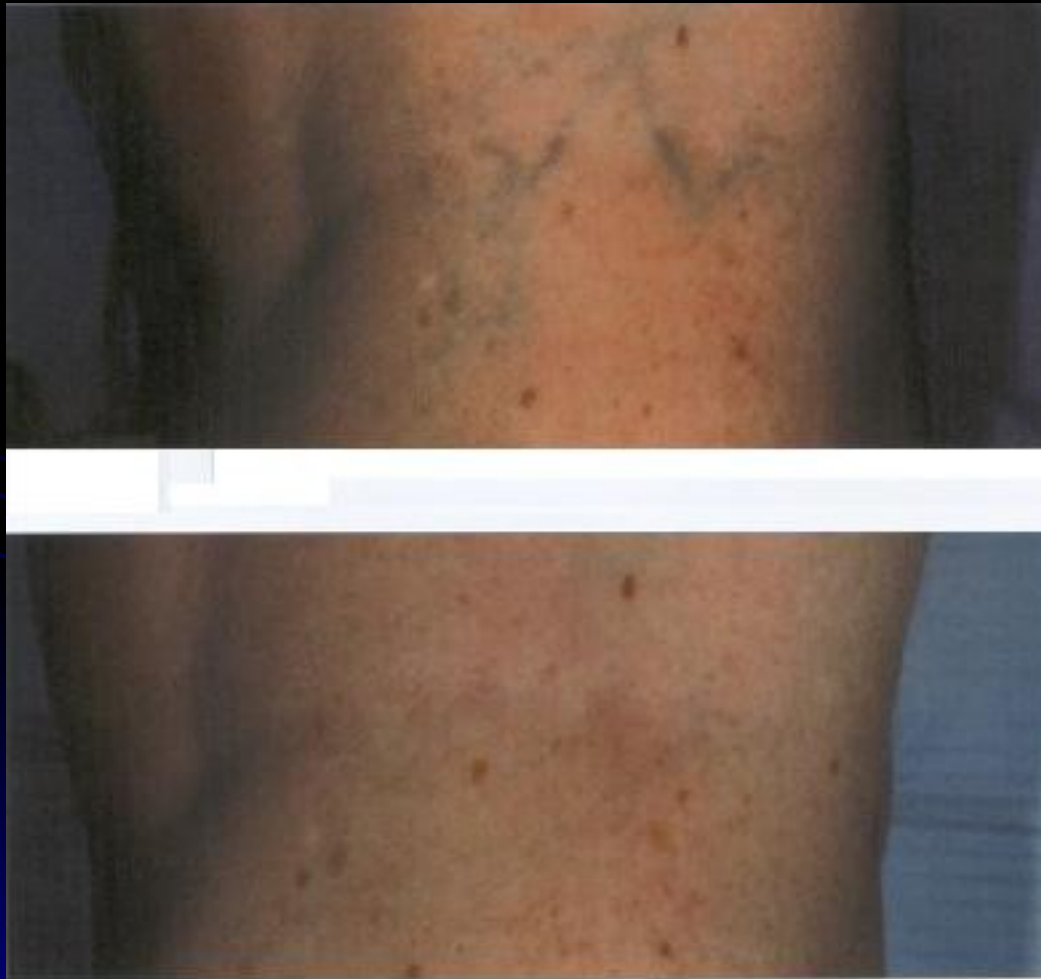Pre Treatment



Number of treatments: 1
1 month after treatment

After Treatment

Female Back of Knee telangiectasia



Pre Treatment

Number of treatments: 1
4 month after treatment

After Treatment

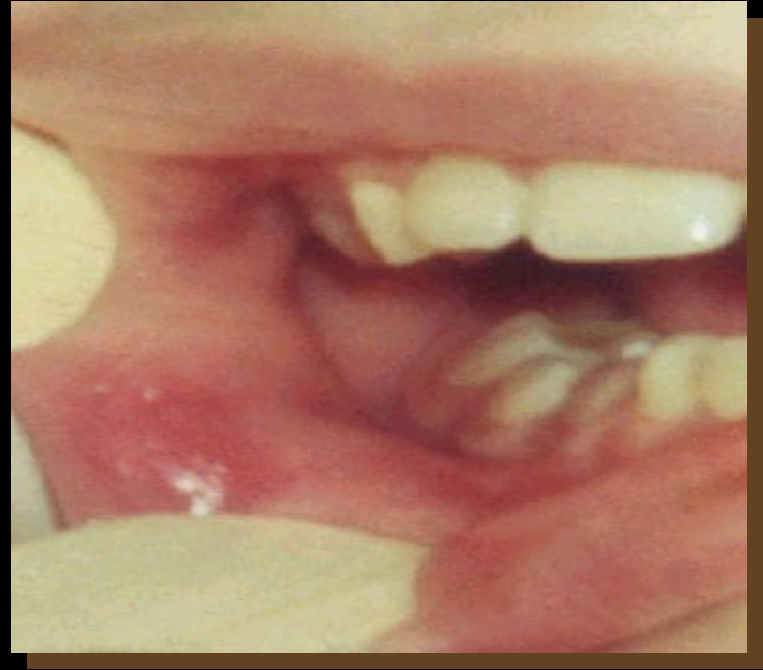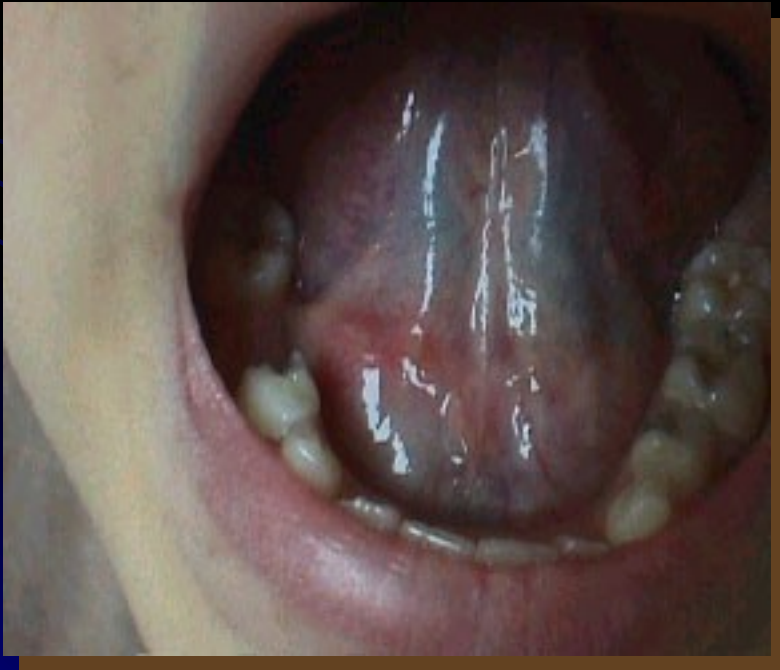MIL Therapy Results in Other Specialities

Stomatitis

Herbal tinctures and medicinal solutions have been used to treat stomatitis but they take a lot of time.

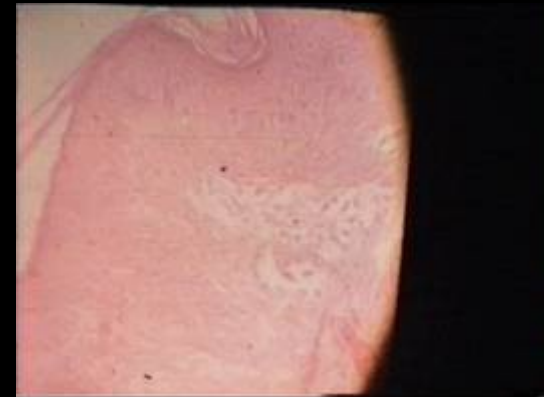
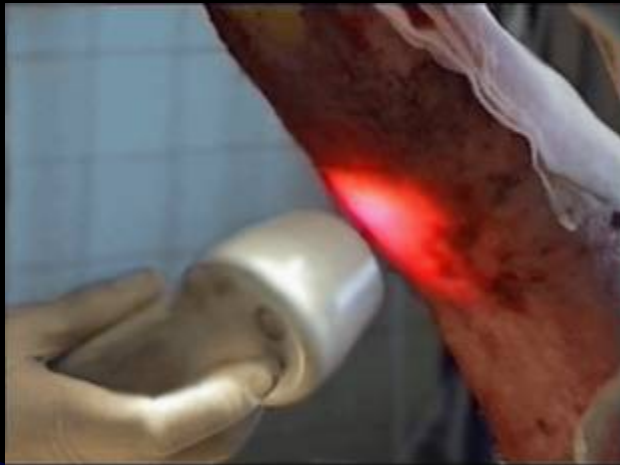As a rule, such treatments produce visible results on the seventh through tenth day. When MIL was applied, we sometimes observed the same effect right after the first treatment.

Full rehabilitation would occur on the third through fifth day.

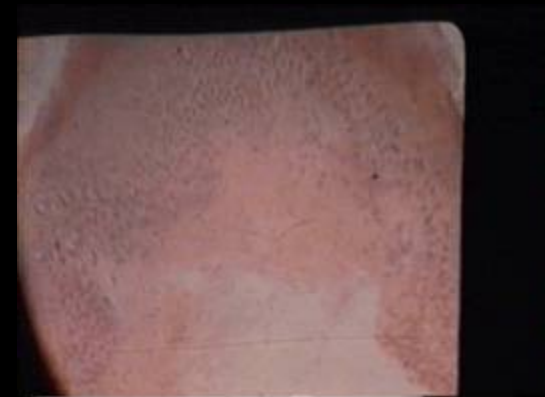

- *Московский НИИ педиатрии и детской хирургии МЗ России*
- *Московская Детская клиническая больница № 9 им.Г.Н.Сперанского*

The skin autograft:



After quantum treatment



Without quantum treatment

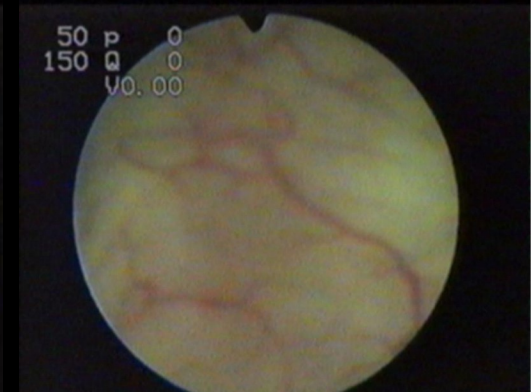
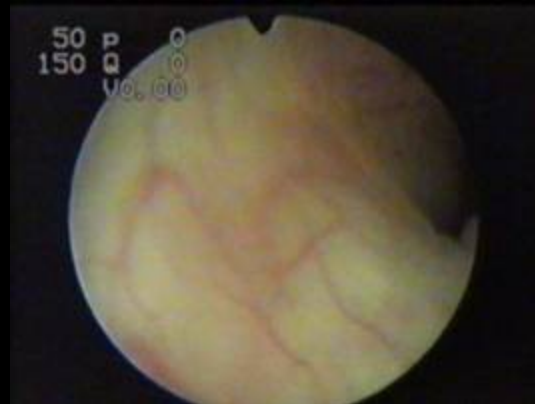
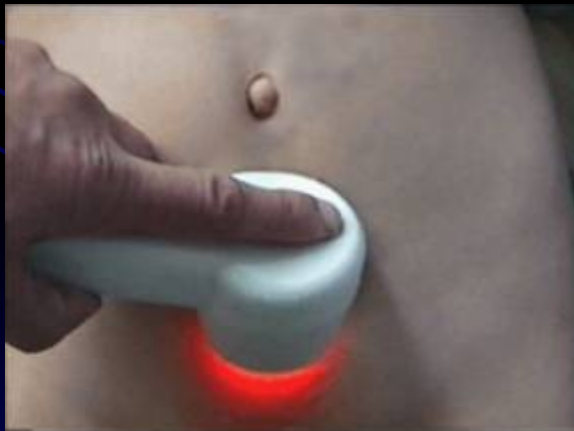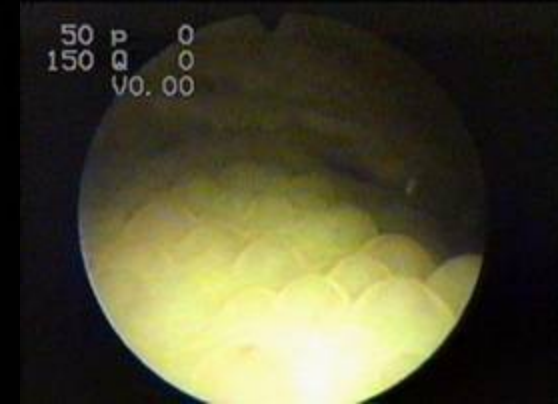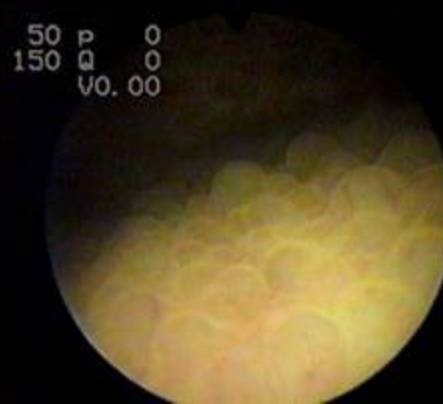
**Quantum treatment
of the skin
autograft at the
burn surface.**

- Московский НИИ педиатрии и детской хирургии МЗ России
- Московская Детская клиническая больница № 9 им.Г.Н.Сперанского

Cystic cystitis.

Grade 4 vesicoureteral reflux.

Preparation for ureter reimplantation.



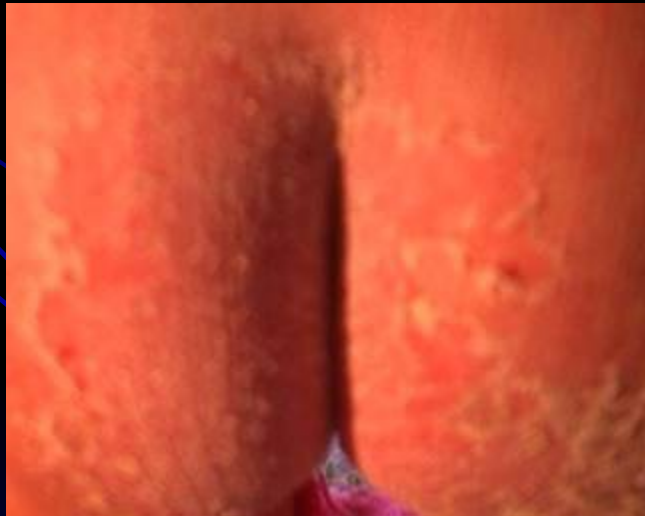Cystic cystitis resolved after 10 procedures.

- Russian Oncological Scientific Center

Post-radiation skin reactions.

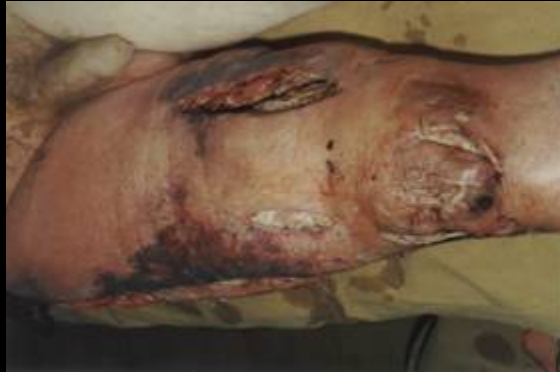Positive effects have been achieved in all cases of treating post-radiation skin reactions.

A comparison of the time needed for the complete disappearance of local manifestations in children who underwent magneto-infrared-laser therapy with historical data has shown that LILR helped to shorten recovery time by 28%.

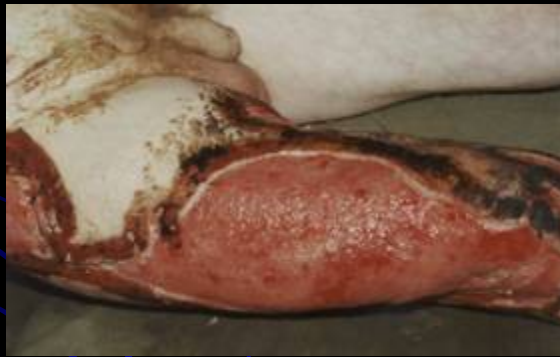

- Research Center of Laser Medicine, Moscow

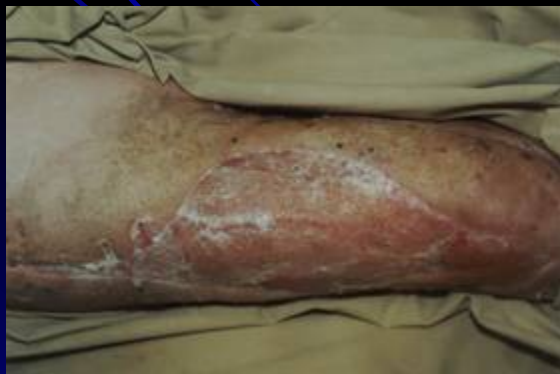Quantum Therapy of Soft Tissue Purulent Wounds



Before treatment



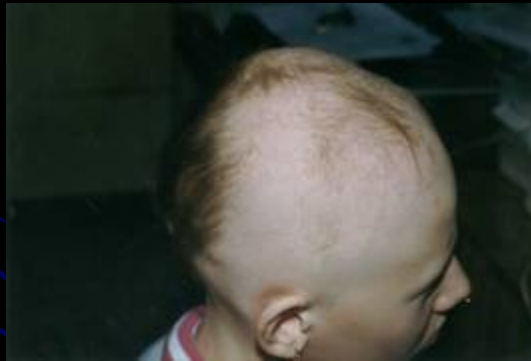After 7 sessions of
quantum therapy



At 20 days following the
start of therapy

Subacute cytomegalovirus infection provoked total alopecia.

Follicles were actually absent in the head skin before treatment (the «polished skin» symptom).



After 5 courses of combined quantum treatment. «Live» follicles and soft unevenly pigmented hair appeared.



After 11 treatment courses. The follow-up period was 11 months. New hair was healthy, glossy and evenly colored.